

Current use of inferior vena cava filters

Joseph G. Magnant, MD, Daniel B. Walsh, MD, Louis I. Juravsky, MD, and Jack L. Cronenwett, MD, *Lebanon, N.H.*

To study possible changes in the clinical use of inferior vena cava (IVC) filters caused by the introduction of percutaneous delivery systems, we reviewed all patients who underwent placement of IVC filters at our institution from 1988 to 1991. Eighty-four patients (52 men and 32 women) ranging in age from 18 to 90 years (mean 67 years) were identified. Filters were required because of contraindications to anticoagulation in 64%, anticoagulation failure in 25%, and preoperative prophylaxis in 11% of patients. The underlying disease was lower extremity deep vein thrombosis in 50% and pulmonary embolism in 45% of patients. Five percent of patients received prophylactic filters without documented thromboembolism. All filters were placed percutaneously by interventional radiologists, 77 through the common femoral vein and 7 through the internal jugular vein. Three types of filters were used. One procedure-related death occurred because of acute IVC occlusion. Fatal pulmonary embolism within 48 hours after filter placement was documented in one patient and suspected in one late death. No other clinically apparent pulmonary embolism or leg swelling occurred after filter placement. Minor complications related to filter placement occurred in 13 patients, but none required operative intervention. Analysis of complication rates of the three filter types was precluded by the small sample size. After a mean follow-up of 11 months, 42 patients (50%) had died of malignancy ($n = 25$), multisystem organ failure (MSOF; $n = 7$), cardiovascular events ($n = 4$), recurrent pulmonary embolism ($n = 2$), cerebrovascular events ($n = 4$), or an unknown cause ($n = 1$). Twenty-three patients (27%) died before hospital discharge. Of these patients, 16 died as a direct result of disseminated cancer or MSOF. Among the subgroup of 48 patients with a history of advanced cancer or MSOF, 20 (43%) died before hospital discharge and an additional 12 died within 6 months of filter placement. Percutaneous placement of IVC filters has not changed the indications for filter placement, nor has this new technique significantly reduced the charge for percutaneous placement (\$5300) compared with operative placement (\$5800). Filter placement in patients with advanced malignancy or MSOF was associated with such poor survival that the benefit of IVC filtration in these patients was questionable. Careful patient selection is required to avoid nonbeneficial filter placement in as many as 25% of patients in whom IVC filter placement initially appears indicated. (*J VASC SURG* 1992;16:701-6.)

Despite increased attention to prophylactic measures to prevent venous thromboembolism, deep vein thrombosis (DVT) and pulmonary embolism remain significant clinical problems. Historically, the management of patients with venous thromboembolism refractory to anticoagulant therapy or with contraindications to anticoagulant therapy was fraught with significant morbidity. Inferior vena cava (IVC) filters have facilitated management of these

patients by providing effective protection from pulmonary embolism, with low morbidity. This success, combined with further refinements in filter-delivery systems, has caused some clinicians to propose use of "expanded" indications for placement of IVC filters.¹⁻⁴ We have previously reported our experience with patients who underwent operative placement of Greenfield IVC filters (Medi-Tech, Watertown, Mass.).⁵ Since 1987, percutaneous placement of IVC filters has supplanted operative filter placement in our center. We undertook this review of the current use of IVC filters to examine the impact of percutaneous placement on indications, complications, survival results, and cost implications.

MATERIAL AND METHODS

Patients undergoing IVC filter placement at the Dartmouth-Hitchcock Medical Center between

From the Sections of Vascular Surgery and Interventional Radiology (Dr. Juravsky), Dartmouth-Hitchcock Medical Center, Lebanon.

Presented at the Fourth Annual Meeting of the American Venous Forum, Coronado, Calif., Feb. 26-28, 1992.

Reprint requests: Daniel B. Walsh, MD, Dartmouth-Hitchcock Medical Center, One Medical Center Dr., Lebanon, NH 03756. 24/1/40474

Table I. Distribution of malignancies

Malignancy	n
Gastrointestinal	
Colon	7
Pancreas	3
Stomach	2
Genitourinary	
Bladder	6
Prostate	5
Hypernephroma	1
Ureteral	1
Gynecologic	
Cervix	2
Endometrial	1
Other solid tumors	
Lung	5
Breast	4
Melanoma	1
Sarcoma	1
Brain	5
Hematologic	
Lymphoma	4
Leukemia	1

1988 and 1991 were identified by hospital records. Charts were reviewed for demographic information including admission diagnosis, primary diseases, and history and stage of malignancy. Indications for filter placement, contraindications to and complications of anticoagulant therapy, and method of documentation of DVT or pulmonary embolism were recorded. Details of filter placement were obtained from interventional radiology procedure notes. Type of filter, introducer size, route of insertion, and procedure-related complications were recorded. Patient follow-up information was obtained by telephone interview, review of hospital records, and contact with patients' primary physicians. Follow-up data, including presence of symptomatic venous insufficiency, defined as significant lower extremity swelling or stasis ulceration, patient survival, and causes of death were recorded. Current charges for percutaneous IVC filter placement were obtained from the radiology billing office. For comparison, estimated charges for operative IVC filter placement were determined from current operating room billing data.

RESULTS

During the study interval, 84 patients (52 men and 32 women) underwent percutaneous placement of IVC filters to prevent pulmonary embolism. There appeared to be increased use over time, because 13 IVC filters were placed in 1988, 29 in 1989, and 36 in 1990. During this same time interval, no IVC filters were placed surgically. Patient age at insertion

Table II. Procedure-related complications

	Bird's nest (n = 42)	Greenfield (n = 33)	Vena-Tech (n = 9)
Filter malposition (n)	3	1	
IVC thrombosis (n)	1	1	
IVC perforation (n)	1		
Insertion site hematoma (n)	2	1	
Insertion vein thrombosis (n)		1	
Introducer problems (n)	1		
Contrast reaction (n)		1	
Total (n)	8	5	0
Incidence (%)	19	15	0

ranged from 18 to 90 years (mean 67 years). Forty-seven patients (56%) had a history of malignancy, of whom 41 (87%) had advanced or widely metastatic disease at the time of filter placement (Table I). In addition, seven patients had multisystem organ failure (MSOF), defined as dysfunction of two or more major organ systems.

Filters were judged to be required by the patients' primary physicians because of contraindications to anticoagulation in 64%, anticoagulation failure in 25%, and preoperative prophylaxis in 11% of patients. Of those with contraindications to anticoagulation, presence of central nervous system mass lesions accounted for 30%, whereas hemorrhage, most commonly gastrointestinal, accounted for the balance. Recurrent pulmonary embolism in the setting of therapeutic systemic anticoagulation constituted "anticoagulation failures." Filters were placed prophylactically in five patients with a history of DVT or pulmonary embolism and in four patients without documented venous disease in anticipation of planned operative procedures. Of the 75 patients with active thromboembolism, the underlying venous disease was DVT in 52% and pulmonary embolism in 48%. Forty-two cases of DVT were documented by duplex scanning (n = 30), contrast venography (n = 5), computerized tomographic scanning for other reasons (n = 4), and on the basis of strong clinical suspicion (n = 3). The diagnosis of pulmonary embolism was documented in 34 patients by ventilation perfusion scanning (n = 27) and pulmonary arteriography (n = 8). Four patients were treated on the basis of duplex-documented DVT alone because of high clinical suspicion of pulmonary embolism.

All filters were placed percutaneously by interventional radiologists. Insertion site was the common femoral vein in 77 and the internal jugular vein in seven patients. Inferior vena cavography was per-

formed routinely coincident with filter placement to evaluate IVC patency and size and renal vein location. Three types of filters were used: 42 Bird's Nest (Cook, Inc., Bloomington, Ind.), 33 Greenfield, and nine Vena-Tech (Vena-Tech, Evanston, Ill.). Bird's Nest and Vena-Tech filters were placed through 12F sheaths. Of the 33 Greenfield filters placed, 32 were stainless steel and required placement through a 24F sheath. One titanium Greenfield filter (14F introducer) was placed late in the series. Selection was dependent on the individual radiologist's preference.

Initial attempt at filter placement was successful in 98% (82/84) of patients. One Bird's Nest filter was malpositioned when it was discharged in the left renal vein. Another Bird's Nest filter opened incompletely. Both of these patients underwent uneventful placement of a second Bird's Nest filter. Filter position was judged to be suboptimal in two other patients but not sufficiently to warrant placement of a second filter. (In one patient anchoring struts of a Bird's Nest filter extended into the renal vein; in another patient one limb of a Greenfield filter extended into the common iliac vein.)

One procedure-related death occurred after placement of a Bird's Nest filter. This patient had acute IVC occlusion immediately after filter placement and died as a direct result within 24 hours. Postmortem examination confirmed acute IVC thrombosis. Fatal pulmonary embolism 24 hours after placement of a Greenfield filter was documented on postmortem examination in one additional patient. Two years after Greenfield filter placement, one other patient died acutely after an orthopedic procedure, presumably of pulmonary embolism, although this was not confirmed. No other clinically apparent episodes of pulmonary embolism occurred. Thirteen minor procedure-related complications occurred in this series. No complications occurred in nine Vena-Tech filter placements. Although there was a trend toward more frequent complications with the Bird's Nest and Greenfield filters, the limited sample size precluded statistical analysis. None of these complications required operative intervention (Table II).

At follow-up, two patients reported presence of symptomatic leg swelling but, after limited follow-up, did not have venous stasis ulceration. After a mean follow-up of 11 months, 42 patients (50%) had died: of malignancy ($n = 25$), MSOF ($n = 7$), cardiovascular events ($n = 4$), cerebrovascular events ($n = 3$), recurrent pulmonary embolism as noted above ($n = 2$), or an unknown cause ($n = 1$). Twenty-three patients (27%) died before hospital discharge, without apparent survival benefit from

IVC filter placement. Of these patients, 16 died as a direct result of disseminated cancer or MSOF. All seven patients with MSOF died before hospital discharge. Other causes of these early, in-hospital deaths included cerebrovascular events ($n = 3$), cardiovascular events ($n = 2$), and pulmonary embolism as noted above ($n = 2$). Of the 48-patient subgroup with a history of advanced cancer at the time of filter placement or MSOF, 20 (43%) died before hospital discharge. An additional 12 patients died within 6 months of filter placement, yielding a 6-month survival rate of 32%. In contrast, 93% (32/36) of patients without a history of advanced malignancy or MSOF survived 6 months or longer (Fig. 1). The few early deaths in this group were the result of cardiovascular events in three and a ruptured basilar artery aneurysm in one patient.

Current hospital and professional charges (excluding hospital stay) for placement of percutaneous IVC filters by interventional radiologists in our institution are \$5322. By comparison, estimated current charges for operative IVC filter placement are \$5820 (Table III).

DISCUSSION

Historically, transabdominal interruption of the IVC by ligation, plication, or clipping for the prevention of pulmonary embolism in patients who had failed conventional anticoagulation or contraindications to or complications of anticoagulant therapy was associated with significant morbidity. Early transjugular or transfemoral filters often resulted in IVC occlusion, which provided only moderate protection against pulmonary embolism at the price of a significant incidence of chronic venous insufficiency or filter migration.⁶⁻¹¹ The Greenfield design of IVC filter improved this by preventing pulmonary embolism in 95% of patients while preserving IVC patency in greater than 95%.¹¹⁻¹³ Filter migration and caval perforation were observed in less than 5% of patients. As originally introduced, its large carrier size made the Greenfield filter best suited for operative placement under local anesthesia. Experience with percutaneous placement resulted in a reported 20% to 33% incidence of local femoral venous thrombosis.^{3,14,15} This led to the development of other filters and modifications of the Greenfield filter that allowed percutaneous placement through smaller carrier systems. In a recent multicenter study, at limited follow-up the titanium Greenfield filter was 97% effective in preventing pulmonary embolism with no evidence of IVC occlusion.¹⁶ The Bird's Nest filter has been reported to prevent pulmonary embolism in

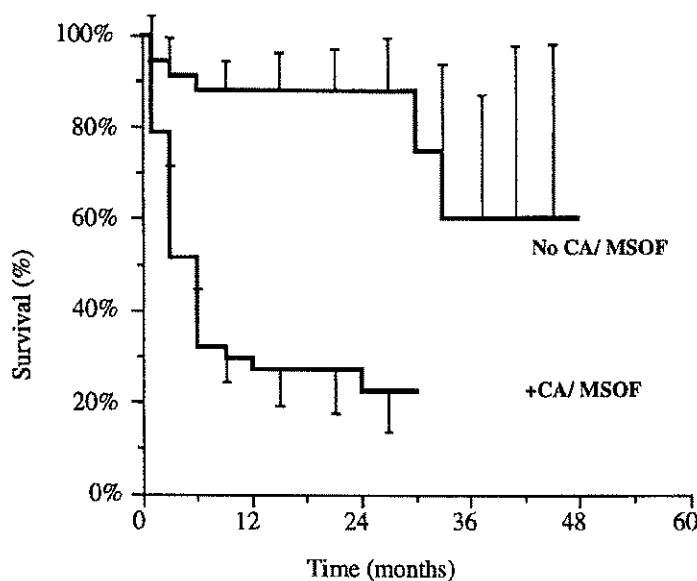


Fig. 1. Life-table comparison of patient survival by group. Standard errors shown are to scale. CA, Cancer; No CA/MSOF, $n = 36$; CA/MSOF, $n = 48$.

Table III. Current charges for vena cava filter placement (procedure only)

	Percutaneous	Operative
Vena cava filter	\$1600	\$1600
Hospital charges	2022	1048
Physician fees		
Radiologist	1700	
Surgeon		2172
Anesthesiologist		1000
Total	5322	5820

97% of patients, while preserving IVC patency in greater than 97%.¹⁷⁻¹⁹ A preliminary report with the Vena-Tech filter has shown similarly excellent results in preventing pulmonary embolism. However, Cull et al.²⁰ reported a significant incidence of Vena-Tech filter misplacements early in their series.

The traditional indications for placement of IVC filters are contraindication to anticoagulation, anticoagulation failure, and prophylaxis in selected patients. With the development of percutaneous IVC filters, some authors have advocated liberalization of the indications for IVC filtration.^{1,2,14} Extended indications for prophylactic filter placement have included patients with chronic obstructive pulmonary disease, critical illness, history of previous pulmonary embolism with marginal cardiac reserve, and patients with cancer thought to be at excessive hemorrhagic risk from anticoagulant

therapy.^{4,14,21,23,24} We have previously reported a series of 41 patients with venous thromboembolism who underwent operative placement of IVC filters between 1979 and 1984.⁵ Although the absolute number of IVC filters placed per year in this study was greater than in our previous study, the distribution of indications for filter placement in our previous study compared with our current series is identical. Contraindication to anticoagulation was the most frequent indication, followed by anticoagulation failure and prophylaxis. The increasing frequency of filter placement in the more recent series is likely attributable to an increase in patient acuity that, in turn, has gradually forced an increase in number of filters placed during the study period.

At our institution the advent of percutaneous IVC filters has resulted in a transition from operative filter placement by vascular surgeons to percutaneous placement by interventional radiologists, removing surgeons from the decision-making process. We initially suspected that this transition, and the perception of these procedures as "risk-free" interventions, would result in a liberalized use of IVC filters for "expanded" indications. However, review of the indications for filter placement in our series of 84 patients does not support this conclusion. The percentage of filters placed for each indication did not vary by placement method from one series to the other.

Although there were more in-hospital deaths in our current series than in our previous experience (26% vs 12%), the comparable poor short-term patient survival in both series highlights the significant early mortality rates of these patients (Table IV).⁵ Mean survival of patients suffering cancer-related deaths in this study was only half that of our previous study. In contrast, survival of those patients without a history of advanced malignancy or MSOF who underwent filter placement was greater than 90% at 6 months. This observation is consistent with the greater prevalence of critically ill patients in this series who demonstrated accepted indications for filter placement and confirms the poor survival in patients with cancer with symptomatic venous thromboembolism that others have observed.²²

In a retrospective review of 32 patients with cancer with venous thromboembolism treated with anticoagulation, Moore et al.²¹ reported a 50% incidence of hemorrhagic complications, half of which were major. This observation and the relative safety of IVC filter placement have led some authors to propose IVC filtration as the initial form of treatment of any patient with cancer with venous thromboembolism.²²⁻²⁴ As opposed to Moore et al., others have questioned the actual risk of anticoagulation in patients with cancer. In a nonrandomized, retrospective review of 49 patients with documented central nervous system tumors and venous thromboembolism, Olin et al.²⁵ found no significant difference in the overall incidence of complications or long-term survival rate between patients treated with anticoagulation ($n = 25$) and those treated with IVC filter ($n = 24$). From these studies, and our own experience, it is clear that the development of venous thromboembolism in patients with advanced malignancy portends a poor prognosis, whether IVC filter or anticoagulation is used. Randomized, prospective studies comparing the outcome of such patients treated with anticoagulants versus IVC filters have not been reported. Thus the decision to expand the indications for filter placement in this group, or to use traditional anticoagulation, remains a clinical quandary.

The patients in this series who underwent percutaneous IVC filter placement with established MSOF or subsequent development of MSOF represent a newly described patient subgroup now more frequently under consideration for IVC filter placement. The short-term patient survival in this group was so poor (100% in-hospital mortality rate) that survival benefit of the vena cava filter was clearly not realized. Analysis of a larger number of patients in this

Table IV. Comparison of studies

	<i>Cut-down approach</i>	<i>Percutaneous approach</i>
Years	1979-1984	1988-1991
No. patients	41	84
Mean age (yr)	57	67
Sex distribution (M/F) (<i>n</i>)	15/26	52/32
Indications (<i>n</i> /%)		
Contraindication to anticoagulation	27/66	51/64
Failure of anticoagulation	10/24	20/25
Prophylaxis	4/10	9/11
Survival		
In-hospital deaths (<i>n</i> /%)	5/12	21/26
Death within 2 mo (<i>n</i> /%)	10/24	21/26
Cancer deaths: mean survival (mo)	6.3	3.5
Filter type (<i>n</i>)	Greenfield (41)	Bird's Nest (42) Greenfield (33) Vena-Tech (9)

subgroup will be required before conclusive predictions can be made regarding which, if any, of these patients will benefit significantly from filter placement.

According to industry sources, between 30,000 and 40,000 IVC filters are placed annually in the United States. In an analysis of the cost of percutaneous versus operative placement of Greenfield filters, Hye et al.²⁶ reported a substantial cost reduction with the percutaneous technique. However, review of the current professional and hospital charges for these procedures at our institution revealed that the transition from "operative" placement by vascular surgeons to "percutaneous" placement by interventional radiologists resulted in only a small reduction in overall charges. Extended follow-up of larger series will be required to define better the cost-effectiveness of this strategy in terms of years of life saved. However, in our center, percutaneous filter placement is at least as cost-effective as operative placement and is not associated with prohibitively high morbidity rates.

In conclusion, percutaneous IVC filter placement has supplanted operative placement, with low major morbidity rates. In our most recent series, the indications for IVC filter placement met the accepted standards in the majority of cases and have not been significantly liberalized by adoption of the percutaneous placement method compared with our previous experience. Data from this study, as well as our previous work, suggest that, despite conformation to the "standard" indications for IVC filter placement, as many as 25% of patients who initially appear to be

candidates for percutaneous IVC filters may not realize significant survival benefit. Specifically, presence of advanced malignancy or MSOF was associated with such poor survival in this series that the ability of IVC filters to enhance survival was questionable. More careful selection of IVC filter recipients, particularly among patients with cancer or MSOF, may increase the proportion of patients likely to benefit from IVC filter placement. Ongoing clinical studies of large patient populations will be useful in determining specifically which patient subgroups are most likely to benefit from filter placement.

We thank Kathleen J. Stone for manuscript preparation and Sharon Besso, RN, and Robert Cole, BS, for assistance in data collection.

REFERENCES

- Golueke PJ, Garrett WV, Thompson JE, Smith BL, Talkington CM. Interruption of the vena cava by means of the Greenfield filter: expanding the indications. *Surgery* 1988;103:111-7.
- Rohrer MJ, Scheidler MG, Wheeler HB, Cutler BS. Extended indications for placement of an inferior vena cava filter. *J VASC SURG* 1989;10:44-50.
- Fink JA, Jones BT. The Greenfield filter as the primary means of therapy in venous thromboembolic disease. *Surg Gynecol Obstet* 1991;172:253-6.
- Pomper SR, Lutchman G. The role of intracaval filters in patients with COPD and DVT. *Angiology* 1991;42:85-9.
- Walsh DB, Downing S, Nauta R, Gomes MN. Metastatic cancer: a relative contraindication to vena cava filter placement. *Cancer* 1987;59:161-3.
- Mansour M, Chang AE, Sindelar WF. Interruption of the inferior vena cava for the prevention of recurrent pulmonary embolism. *Am Surg* 1985;51:375-80.
- DeLaria GA, Hunter JA, Serry C, Goldin MD. Thromboembolism and cancer: treatment with the Hunter balloon. *J VASC SURG* 1984;1:670-4.
- Hunter JA, DeLaria GA, Goldin MD, et al. Inferior vena cava interruption with the Hunter-Sessions balloon: eighteen years' experience in 191 cases. *J VASC SURG* 1989;10:450-6.
- Hunter JA, DeLaria GA. Hunter vena cava balloon: rationale and results. *J VASC SURG* 1984;1:491-7.
- Wingerd M, Bernhard VM, Maddison F, Towne JB. Comparison of caval filters in the management of venous thromboembolism. *Arch Surg* 1978;113:1264-71.
- Cimochowski GE, Evans RH, Zarins CK, Lu CT, DeMeester TR. Greenfield filter versus Mobin-Uddin umbrella: the continuing quest for the ideal method of vena caval interruption. *J Cardiovasc Surg* 1980;79:358-65.
- Greenfield LJ. Current indications for and results of Greenfield filter placement. *J VASC SURG* 1984;1:502-4.
- Greenfield LJ, Michna BA. Twelve-year clinical experience with the Greenfield vena caval filter. *Surgery* 1988;104:706-12.
- Pais SO, Tobin KD, Austin CB, Queral L. Percutaneous insertion of the Greenfield inferior vena cava filter: experience with ninety-six patients. *J VASC SURG* 1988;8:460-4.
- Mewissen MW, Erickson SJ, Foley WD, et al. Thrombosis at venous insertion sites after inferior vena cava filter placement. *Radiology* 1989;173:155-7.
- Greenfield LJ, Cho KJ, Proctor M, et al. Results of a multicenter study of the modified hook-titanium Greenfield filter. *J VASC SURG* 1991;14:253-7.
- Roehm JF Jr, Gianturco C, Barth M, Wright KC. Percutaneous transcatheter filter for the inferior vena cava. *Radiology* 1984;150:255-7.
- Roehm JOF Jr, Johnsrude IS, Barth MH, Gianturco C. The bird's nest inferior vena cava filter: progress report. *Radiology* 1988;168:745-9.
- Roehm JOF Jr. The Bird's Nest filter: a new percutaneous transcatheter inferior vena cava filter. *J VASC SURG* 1984;1:498-501.
- Cull DL, Wheeler JR, Gregory RT, Snyder SO Jr, Gayle RG, Parent FN III. The vena tech filter: evaluation of a new inferior vena cava interruption device. *J Cardiovasc Surg* 1991;32:691-6.
- Moore FD, Osteen RT, Karp DD, Steele G Jr, Wilson RE. Anticoagulants, venous thromboembolism, and the cancer patient. *Arch Surg* 1981;116:405-7.
- Cantelmo NL, Menzoian JO, Legerfo FW, Fasulo G, Mozden PJ. Clinical experience with vena caval filters in high-risk cancer patients. *Cancer* 1982;50:341-4.
- Cohen JR, Tenenbaum N, Citron M. Greenfield filter as primary therapy for deep venous thrombosis and/or pulmonary embolism in patients with cancer. *Surgery* 1991;109:12-5.
- Calligaro KD, Bergan WS, Haut MJ, Savarese RP, DeLaurentis DA. Thromboembolic complications in patients with advanced cancer: anticoagulation versus Greenfield filter placement. *Ann Vasc Surg* 1991;5:186-9.
- Olin JW, Young JR, Graor RA, Ruschhaupt WF, Beven EG, Bay JW. Treatment of deep vein thrombosis and pulmonary emboli in patients with primary and metastatic brain tumors. *Arch Intern Med* 1987;147:2177-9.
- Hye RJ, Mitchell AT, Dory CE, Freischlag JA, Roberts AC. Analysis of the transition to percutaneous placement of Greenfield filters. *Arch Surg* 1990;125:1550-3.

Submitted April 14, 1992; accepted June 23, 1992.